



Vacuum Assisted Delivery Procedures

Dr Peter de Jong

VACUUM ASSISTED DELIVERY PROCEDURES

Dr Peter de Jong MD

MBChB, FRCOG, FCOG, MMed

Dept of Obstetrics and Gynaecology
University of Cape Town, Groote Schuur Hospital,
Cape Town, South Africa

Christian Barnard Memorial Hospital,
Cape Town, South Africa

All rights reserved. No part of this publication may be reproduced or transmitted in any form or by any means, electronically or mechanically, including photocopying, recording or any information storage or retrieval system, without either prior permission in writing from the publisher or a licence permitting restricted copying.

Vacuum Assisted Delivery Procedures

| | |
|--|----|
| 1. Introduction | 1 |
| 2. Objectives of this book | 3 |
| 3. Development of the Modern Obstetric Vacuum Extractor | 4 |
| 4. Applied Pelvic and Fetal Anatomy | 8 |
| 5. Description of the Equipment | 12 |
| 6. Indications and contra-indications for vacuum delivery | 18 |
| 7. Assessment and selection of cases for vacuum delivery | 23 |
| 8. Before proceeding to vacuum delivery | 27 |
| 9. Principles, techniques and clinical use of the vacuum extractor | 30 |
| 10. The use of vacuum assisted delivery at Caesarean Section | 39 |
| 11. Complications of vacuum delivery | 42 |
| 12. Training measures | 51 |
| 13. Cleaning and sterilizing the equipment | 53 |
| 14. Summary and conclusions | 56 |

1. INTRODUCTION

The obstetric vacuum extractor (also known as the ventouse) has been used for many years to assist women during parturition. Just as the design of the various instruments has changed over the years, the methods employed in performing vacuum extractions have been refined. The modern Silc Cup instrument has developed from the original Malmström device, and represents an easy, safe and efficient method for assisting women to deliver a healthy baby with a minimum of trauma to both the mother and infant. The literature is replete with detailed descriptions of the various models of vacuum extractors, and the methods used in delivery.

However, the great variety of instruments and methods may cause confusion and there is a need for a simple, clear and concise text to describe the use of the modern obstetric vacuum extractor. This booklet has been written by a practicing obstetrician with a wide experience in the use of the modern ventouse. The following chapters outline in considerable detail the use of vacuum extractors, including a brief description of the devices, assessment of the case, application of the various types of cups, and delivery of the baby. The author covers pitfalls in the procedure, safety aspects and the complications that may arise.

Finally, care and cleaning of the instrument is described. Each chapter ends with a brief summary of the cardinal points of practice, to emphasise important facts to remember. To improve accessibility and brevity, references are not included. For the academic wishing to delve deeper into the subject, a wealth of standard texts and literature is available which may be consulted.

This book is for the practicing midwife or obstetrician who requires a clear, concise presentation of the material facts. It is presumed that the reader has a basic training in midwifery, and that a certain degree of understanding of the discipline exists.

2. OBJECTIVES OF THIS BOOK

Careful study of the text will allow the reader to –

- Acquire knowledge of the background development of the modern obstetric vacuum extractor.
- Understand how the design of the instrument progressed from the earliest models to the modern variants.
- Grasp the basic anatomy pertinent to the selection of the appropriate vacuum cup.
- Assess the progress of labour and the suitability of the case for vacuum delivery.
- Select the correct device for the type of procedure to be performed.
- Review the inclusion and exclusion criteria prior to application of the instrument.
- Apply the vacuum cup easily, safely and efficiently, after counselling the mother.
- Perform a safe vacuum delivery.
- Appreciate common pitfalls and complications, and deal with unexpected circumstances.
- Clean and examine equipment, and prepare the system for further use.

The text is not designed to be read as an academic exercise, and is essentially a practical tool to be kept on the labour ward to be read and understood by midwives and obstetricians alike.

3. DEVELOPMENT OF THE MODERN OBSTETRIC VACUUM EXTRACTOR

James Simpson is credited with the first description of a workable instrument in 1849, but the design of the Swedish obstetrician Tage Malmström in the 1950's introduced a new impetus in the acceptance of the device. Malmström's metal cup was a hollow hemisphere that allowed the formation of a chignon, or caput succedaneum. A short traction chain attached centrally to the cup passes through a length of rubber tubing, secured by means of a small clip to a traction handle. A longer length of rubber tubing is connected to a reservoir with a rubber stopper. The vacuum in the bottle was achieved with a metal hand-pump, and the vacuum was estimated by means of a gauge attached to the rubber stopper. The **Malmström Cup** device is still in widespread use, and is known today as «the original vacuum extractor.» It is available with 3 suction cups of 40 mm, 50 mm and 60 mm diameter.

Since the chain and rubber tubing join the cup centrally, it will be shown that this design is most appropriate for the foetus in the occipito – anterior position. Hence, this design of cup is also known as the «Malmström Anterior Cup». The entire system consists of the metal cup (in 3 sizes), the chain and tubing, a metal traction handle with stop clip, the plastic vacuum bottle and rubber stopper, the vacuum gauge and a standard stainless steel vacuum pump.

Today, electric vacuum pumps allowing electric vacuum delivery (EVD) are common. These versatile devices are especially designed to allow the physician greater freedom and safety in performing a vacuum assisted delivery, and allowing the nurse/midwife to focus on the patient and her partner.

When the traction is applied at right angles to the cup, as may occur in the well-flexed foetus in the occipito-anterior position with an engaged head, delivery is easily achieved.

However, the above situation, although common, is not invariably present. When traction is applied oblique to the plane of the cup, loss of vacuum may occur and the cup may even detach. Occasionally the maternal perineum may interfere with the centrally placed tubing and chain, which would not allow for an efficient direction of traction and cause maternal discomfort. Since malpositions of the fetal head often made vacuum delivery desirable, it became necessary to modify the Malmström original «anterior cup» for these altered obstetrical circumstances.

To overcome the above difficulties of attempting a vacuum delivery on any position other than the well flexed occipito - anterior position, Dr Bird introduced a modified vacuum extractor in the 1970's. He addressed the problem of cup detachment when oblique cup traction was applied by separating the suction and traction systems. Whilst the traction chain in the Bird «Modified Vacuum Extractor» remained central on the cup, the suction nipple was moved eccentrically on the cup dome lessening the tendency of the cup to detach during traction. When compared to Malmström's design there is considerably less risk of the **Bird Cup** slipping off the fetal scalp when tension is applied at an angle to the cup. Furthermore, the device may be easier to apply to the correct position on the fetal scalp with a simpler traction apparatus that is easier to assemble. These cups,

classed as the «anterior suction cups» are available in 40 mm, 50 mm and 60 mm diameters. To increase the flexibility and range of movement of the cup, particularly with an occipito-posterior position where the posterior fontanelle is obscured from view and rather more inaccessible, Bird repositioned the suction nipple to the lateral sidewall of the cup. This cup is recommended for use when the fetal head is in the posterior or lateral occipital position, when clearly the suction tubing would otherwise restrict and obstruct correct placement. The «posterior suction cup» is only supplied with a 50 mm diameter.

Finally, to reduce the risk of trauma to the fetal scalp, a soft cup manufactured in medical grade silicone was introduced in 1984. This device, the **Silc Cup** is available with an inner diameter of 50 mm or 60 mm. The advantages of the Silc Cup include ease of application, effective adherence to the fetal scalp without the formation of a chignon, and minimal risk to both the mother and baby during its use.

The **Single Use Silc Cup** is of similar design as the **Silc Cup**, but manufactured from a different grade of material. Also on the market is the plastic, **Single Use Bird Cup**, which obviates the necessity of cleaning and re-sterilization, whilst maintaining the design of the original patent. All devices are operated by means of a vacuum pump that creates a vacuum in series with a reservoir. Various pump options are available, depending on the requirements of the operator.

The CaesAid Cup is a recent development which allows easy delivery of the fetal head at caesarean section. It is used in conjunction with an electric vacuum pump. The following chapters will provide a more detailed description of the designs already mentioned, with notes on how to assess cases appropriately, and how to apply the cups correctly to achieve a safe and satisfactory outcome.

SUMMARY:

DEVELOPMENT OF THE VACUUM EXTRACTOR

- Malmström developed the modern obstetric vacuum extractor in the 1950's.
- The «Malmström anterior cup» has the traction chain inside the vacuum tube and fixed central to the metal cup.
- The design works best when traction is perpendicular to the cup, and so the design is suited to a well-flexed occipito-anterior foetus.
- In the 1970's the Bird «Modified Vacuum Extractor» had the traction chain placed centrally but an eccentric vacuum nipple.
- This device allows easy application in the correct position, and some degree of oblique traction is possible.
- The Bird «posterior suction cup» has the vacuum nipple on the lateral side-wall of the cup, allowing occipito-lateral and occipito-posterior placements.
- In 1984 a «soft cup» made from silicone rubber was introduced, allowing atraumatic, safe vacuum delivery in well-flexed occipito-anterior positions with the presenting part below spines.
- Nowadays, single use variants of the Silc Cup and the Bird Cup are available.
- The CaesAid Cup facilitates easy delivery of the fetal head at a caesarean section.

4. APPLIED PELVIC AND FETAL ANATOMY

INTRODUCTION

During its passage through the pelvis the fetal head undergoes a prescribed set of manoeuvres including descent, flexion, internal rotation and then birth by extension. The most favourable diameters are presented when the fetal head is in the well-flexed occipito-anterior position.

THE PELVIS

The conformation of the pelvic floor muscles results in anterior rotation of the fetal head as it descends. It follows that adequate uterine contractions and maternal expulsive effort are important in causing engagement and descent of the fetal presenting part. The birth canal is in the shape of a curved tube with diminishing calibre, encouraging flexion during descent. The pelvic curve is important to appreciate and consider, since as fetal descent occurs the vector of traction alters accordingly. Knowledge of the normal pelvic dimensions is paramount in the pelvic assessment prior to considering vacuum delivery in the second stage of labour. The

zones of the pelvis are illustrated in Fig 1.

Any deviation from the normal dimensions in the pelvic inlet, midcavity and outlet may not only cause abnormalities of head position, flexion and asynclitism, but also result in arrest of the progress of the second stage. Prior to embarking on any va-

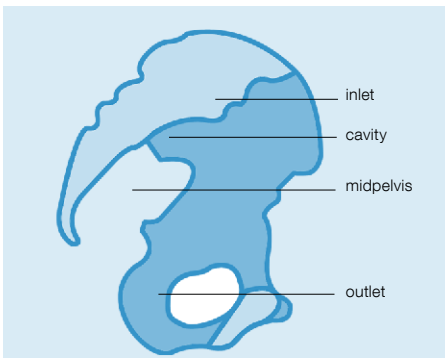


Fig 1. The «zones» of the pelvis

cuum training process, the midwife or obstetrician must carefully review pelvic anatomy and consider the pelvic dimensions relative to those of the fetal head. Variations of pelvic shape must be considered, since many women may have android and not gynaecoid type pelvic bone structures.

Table 1. Measurements of the normal pelvis in cm

| | |
|---|---------|
| Antero-posterior of brim (Obstetric conjugate) | 12 cm |
| Transverse of brim | 13 cm |
| Ischial bispinous | 10.5 cm |
| Antero-posterior of outlet | 10.5 cm |
| Sub-pubic angle | 85° |

THE FETAL HEAD

Whilst the fetal head is generally ovoid in shape, prolonged labour with the occipit lateral or posterior may cause moulding with the formation of a parietal caput succedaneum.

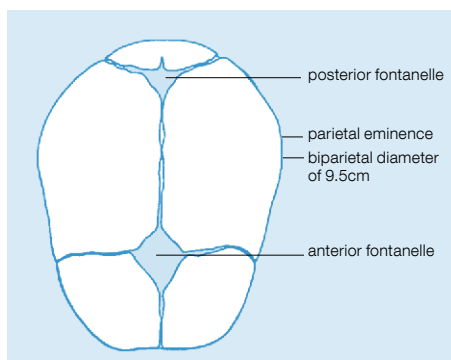


Fig 3. The fetal skull showing the biparietal diameter

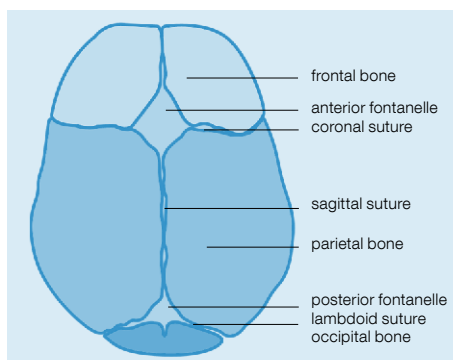


Fig 2. The fetal skull from above showing important obstetrical landmarks

Some moulding of the head during engagement and descent is normal, and does not interfere with internal rotation (Fig 2).

PRESENTING DIAMETERS

With the vertex presenting and the head flexed and synclitic, the suboccipitobregmatic and biparietal diameter of 9.5 cm occurs (Fig 3). The posterior fontanelle is easily accessible, and the sagittal suture is central in the birth canal. Deflexion lengthens the sagittal diameter, and brings the anterior fontanelle into play. When asynclitism is present with deflexion, the sagittal and coronal diameters increase. This increase in the fetal presenting dimensions may obstruct further descent, or alternatively, good contractions may cause flexion, synclitism and anterior rotation of the occiput.

Because of the anatomical arrangement of the head pivoting on the fetal neck, descent of the head causes flexion. Similarly, any traction to the fetal head must necessarily be over

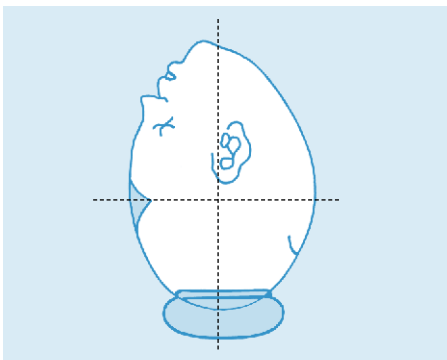


Fig 4. In a fully flexed head the mento-vertical diameter is along the pelvic axis.

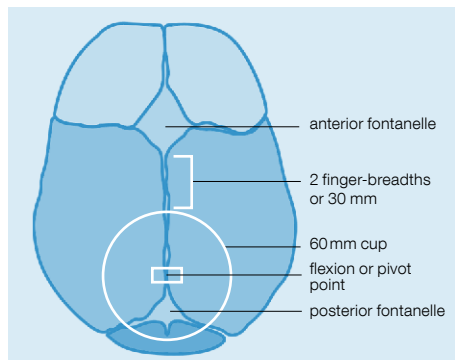


Fig 5. The fetal skull from above showing the correct placement of the vacuum extractor, over the flexion point.

or behind the pivoting point of flexion, otherwise traction will result in deflexion (extension) of the fetal head.

In a fully flexed head the mentovertical diameter is along the pelvic axis (Fig 4). The correctly applied vacuum cup must be along this plane of alignment, which is just anterior to the posterior fontanelle. This position is sometimes termed the «flexion point», over which the correctly applied vacuum cup is positioned (Fig 5).

SUMMARY: PELVIC AND FETAL ANATOMY

- The maternal pelvis is a curved tube of diminishing calibre.
- The normal obstetrical conjugate is 11 cm to 12 cm, at the pelvic inlet.
- The smallest pelvic diameter is in the midpelvis, between the ischial spines, and this distance is 10.5 cm.
- At the pelvic outlet, the antero-posterior diameter between the symphysis and the sacro-coccygeal junction is 11 cm.
- A well-flexed synclitic head has a sub-occipitobregmatic and biparietal diameter of 9.5 cm.
- The well-flexed occipito-anterior position presents the diameter of 9.5 cm. Other positions or head deflexion results in less favourable presenting diameters.
- The «flexion point» is immediately anterior to the posterior fontanelle, along the mentovertical diameter.
- The correctly applied vacuum cup is positioned over this flexion point.

5. DESCRIPTION OF THE EQUIPMENT

INTRODUCTION

Although the currently available models have been briefly described in a previous chapter, a more detailed description of the equipment follows.



Fig 6. Malmström cup showing metal stop clip.

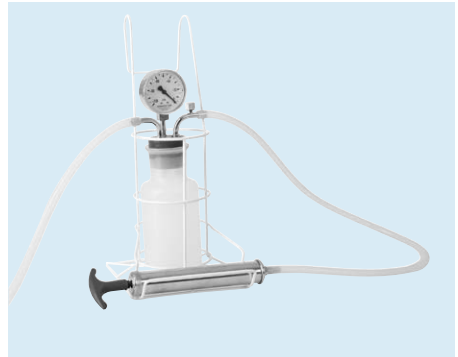


Fig 7. Hand operated vacuum extractor

THE MALMSTRÖM CUP AND VACUUM BOTTLE

The original vacuum extractor or «Malmström anterior cup» is a stainless steel hemisphere with convex sidewalls, available in 40, 50 and 60 mm diameters. The suction nipple is placed centrally on the cup, allowing attachment of the 32 cm long silicone rubber tubing. The traction chain, attached to a stainless steel bottom plate, passes through the vacuum nipple and is connected to the steel traction handle by means of a small metal stop clip (Fig 6).

The 120 cm rubber tube attaches the traction handle to the plastic vacuum bottle. A vacuum gauge measures the negative pressure in the vacuum bottle to ensure a correct operating vacuum. A 50 cm long silicone rubber tube connects the

vacuum bottle to the vacuum pump, which may be hand operated or electric, depending on personal preference (Fig 7). Alternatively a hand operated plastic pump in series with a reservoir may be employed to create the necessary vacuum.

ELECTRIC VACUUM PUMPS

Traditionally the manual vacuum pump has been employed to maintain the desired vacuum. Today, electric vacuum pumps are being used to achieve a vacuum and keep the pressure at the desired level. There are many benefits in using electric vacuum delivery (EVD) instead of manual vacuum equipment, especially if the EVD system is purpose-built for obstetric vacuum delivery.

- Better control of suction
- Fewer cup «pop-offs» due to vacuum reservoir
- Equipment compensates for minor air leakages
- Precise, repeatable setting of desired vacuum pressure
- Equipment regulates vacuum pressure, not physician
- Physician is hands-free from suction source
- Fast vacuum build-up
- Improved visualization of the birth field
- Increased focus on mother and baby
- Increased safety
- Less potential for human error

Benefits of EVD

Modern custom-made EVD pumps are small and mobile, with both hand and foot-switch operation. This allows the physician to operate the pump while not interfering with the instrumental delivery. Mobility allows the pump to be suitably placed and moved without hindrance. Custom-made EVD's are designed for near-silent operation that does not distract the patient or her partner during delivery. Such purpose-built EVD devices that are particularly suitable are the electric pumps **Basic** or **Dominant Flex** (Fig. 8). It combines the above properties with a clever ergonomic design and neat appearance. The pump is easy to keep clean due to its elegant shape, and has easily accessible controls to select and maintain safe vacuum pressure.



Fig 8. Electric vacuum pump and foot vacuum regulator

Electric vacuum pumps must have a transparent reservoir, with suitable rubber seals and gaskets to prevent leakage and soiling. All controls and indications must be clear and accessible, eliminating the need for assistance when performing a procedure and freeing up the nurse or midwife to be with the mother. A consistent pressure is achieved within a few seconds and effortlessly maintained at the desired level, reducing the risk of

accidental cup detachment. Between contractions the vacuum pressure may be reduced to not less than -40 kPa to reduce fetal scalp stress. The EVD pump must be properly maintained and serviced by qualified personnel to avoid breakdowns, leakages and malfunctioning.

BIRD CUPS

(The modified Vacuum Extractor)

The original Bird cups have a chain as the mechanism for traction which is separate from the suction tube (Fig 9). The «anterior cup» has the metal suction nipple eccentrically and obliquely placed on the dome (Fig 9a), whereas the «posterior cup» has the nipple attached to the side wall of the cup (Fig 9b). The traction apparatus consists of a welded chain attached permanently to a small, centrally-situated half-ring



Fig 9. Bird's rigid metal vacuum extractor cup. Note the eccentrically located vacuum port and the fixed traction chain.

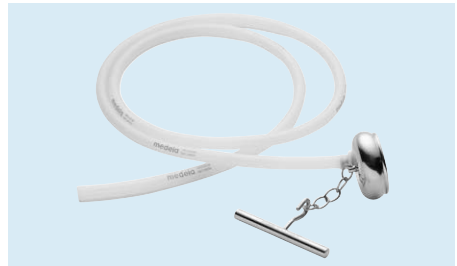

Fig 9a. Bird anterior cup and traction handle



Fig 9b. Bird posterior cup and traction handle

set into a slight depression on the dome of the cup, and a separate handle which can be hooked into an appropriate link of the chain after the cup has been applied to the fetal head (Fig 9b).

A meshed bottom plate made of polypropylene material is placed within the cup and cannot fall out as its diameter is a little larger than the diameter of the mouth of the cup. Theoretically, the bottom plate mesh functions to maintain a clear space between the fetal scalp and the vacuum tube and ensures that an effective vacuum pressure may be maintained. A length of silicone rubber tube, approximately 150 cm long, is attached to the cup's suction pipe and may be secured against slipping off by a plastic locking ring. The other end of the tubing is attached to a suitable vacuum pump.

THE SILC CUP

The Silc Cup is made of medical grade silicone rubber and is available in two sizes, 50 and 60 mm inner diameter (Fig 10). The instrument is made in one piece and consists of a suction cup and handle. The cup has a smooth external surface, but there is a small longitudinal ridge which makes it possible to observe any rotation.

A short metal pipe at the top of the handle is attached to a length of tubing connecting the cup to the vacuum apparatus. The inside of the cup is



Fig 10. Silc Cup

lined with small projections, which enable the air between the cup and the fetal head to be evacuated and ensure that the cup sucks firmly against the scalp. Both the head and the soft suction cup deform, thereby ensuring optimal adhesion and minimizing trauma to the fetal scalp. The Silc Cup is connected to an electric or manual pump by silicone rubber tubing.

The vacuum recommended for the cup with a 50 mm inner diameter is -80 kPa and for the 60 mm cup -60 to -80 kPa. There are no valves in the Silc Cup, so adjustment to the level of partial vacuum is achieved by means of a regulator valve on the suction pump.

SUMMARY:

DESCRIPTION OF THE EQUIPMENT

- Malmström Cup – an anterior cup with a central vacuum and traction placement.
- Available in 40, 50 and 60 mm steel cup sizes.
- Bird cups – «anterior cup» has a central chain and eccentric vacuum nipple. Available in 40, 50 and 60 mm steel cup sizes.
- Bird «posterior cup» has the central chain, but laterally-placed vacuum nipple on the side-wall of the metal cup. Available in 50 mm steel cup size.
- The Silc Cup is a one-piece moulded silicone rubber cup available in 50 and 60 mm diameters.
- Single use variants of the Bird anterior cup and the Silc Cup are available

6. INDICATIONS AND CONTRA-INDICATIONS FOR VACUUM ASSISTED DELIVERY

INDICATIONS

There are both maternal and fetal indications, and these are outlined as follows:

| Maternal indications | |
|--|--|
| – Shortening of second stage of labour | – maternal exhaustion |
| | – reduced maternal effort, i.e. hypertensives, cardiacs, previous caesarean sections |
| – Prolonged second stage | – poor progress of 2 nd stage |
| | – malposition of presenting part |
| | – deflexed head |
| | – asynclitism |
| – Special cases | – vacuum at caesarean section |
| | – delivery of second twin |
| Fetal indications | |
| – Fetal distress | – expedite delivery with abnormal CTG, bradycardia. |

Table 2: *Indications for Vacuum Assisted Delivery.*

While indications for operative intervention are very variable and depend on the clinical situation, operator skill and experience, the table covers the main indications for vacuum delivery.

Shortening of the second stage of labour may be required to assist an exhausted mother, or if all sensation is lost due to an epidural anaesthetic. Maternal effort may be reduced if the woman is a cardiac case, or should not Valsalva because of hypertension. If she has a uterus scarred by a previous caesarean section, a vacuum may assist the delivery and reduce strain on a scarred uterus.

When the second stage of labour is prolonged due to poor fetal head flexion or a malposition of the vertex, application of a vacuum cup may correct this.

Occasionally, vacuum delivery may be useful in special circumstances. For example, an experienced obstetrician may employ a vacuum to deliver the second twin. At caesarean section with a high presenting part, vacuum delivery with a CaesAid device may deliver the baby without delay.

Recent work has shown that in the case of fetal distress, for example with an abnormal CTG or fetal bradycardia, a vacuum delivery is quick and efficient at expediting delivery and may be safely used instead of forceps.

CONTRA-INDICATIONS FOR VACUUM ASSISTED DELIVERY

The following table suggests common contradictions for the use of a vacuum extractor. While a short list of contra-indications is given, it is unhelpful to be dogmatic in the approach to clinical situations. Certainly if cephalopelvic disproportion is suspected because of a high unengaged head, especially with excessive caput and moulding, then it would be foolhardy to attempt a vacuum delivery. In the uncooperative subject, poor coordination between uterine contractions and bearing down efforts may be expected,

and a failed vacuum may result. If a forceps delivery fails it is foolish to attempt a vacuum delivery. Similarly, if a vacuum delivery fails it is ill-advised to attempt a forceps delivery. When the vacuum cup disengages twice, re-application of a vacuum cup is pointless and may result in failure. In this case, it is best to proceed to an emergency caesarean section.

Maternal contra-indications

- Unengaged fetal head
- Cephalopelvic disproportion (CPD)
- Cervix not fully dilated
- Excessive caput/moulding
- Uncooperative subject
- Failed forceps
- Cup disengaged twice (or more)

Fetal contra-indications

- Prematurity <36 weeks gestation
- Abnormal presentation
- Fetal abnormalities
- Bleeding disorders
- Osteogenesis imperfecta

Table 3: *Contra-indications for vacuum delivery*

FETAL CONTRA-INDICATIONS

When the baby is premature or growth restricted, certainly if less than 36 weeks gestational age, it may be unwise to apply a vacuum cup. Clearly if the baby has an abnormal presentation, then a vacuum delivery is contra-indicated. Fetal distress is not considered to be a contra-indication, since it is no slower than a forceps delivery.

TRIAL OF VACUUM

Under certain circumstances, some degree of uncertainty may exist as to whether or not the vacuum assisted delivery procedure will be easy and straight forward. Occasionally, even when the head is engaged, it may be difficult to be certain of the position of the vertex. Perhaps one is unsure of the fetal size or pelvic capacity. Whenever a degree of doubt exists, it would be wise to carefully counsel the patient and perform a «trial of vacuum» by applying the instrument in theatre.

Should the application or procedure fail, then one may proceed directly to caesarean section without any delay. If the procedure is gently attempted in theatre the temptation to succeed despite prudent judgement is avoided, and the pejorative stigma of a «failed vacuum» does not apply.

**SUMMARY:
INDICATIONS AND CONTRA-INDICATIONS**

Indications for Vacuum Assisted Delivery

- Maternal
- shortening of 2nd stage
 - prolonged 2nd stage
 - special indications

- Fetal
- fetal distress

Contra-indications for Vacuum Assisted Delivery

- Maternal
- unengaged presenting part
 - CPD
 - undilated cervix
 - excessive caput/moulding
 - poor co-operation
 - failed forceps
 - cup slips off twice

- Fetal
- prematurity
 - abnormal presentation
 - fetal abnormalities

7. ASSESSMENT AND SELECTION OF CASES FOR VACUUM ASSISTED DELIVERY

CLINICAL EVALUATION

Cephalopelvic disproportion (CPD) results from an absolute or relative disparity between the dimensions of the bony pelvis and the fetal head. Failure to progress in labour is caused by relative or absolute CPD, inadequate uterine powers, ineffectual bearing down effort or a combination of factors. Abnormal fetal head position, asynclitism or poor flexion may contribute towards relative CPD.

A comprehensive assessment of the maternal condition and progress of the first stage of labour is mandatory, reviewing all the details of each clinical examination and intervention. Note whether oxytocin was required, and the quality of uterine activity that resulted. Occasionally CPD may result in slow progress and poor uterine activity in primiparous women, and oxytocin use will not overcome CPD. In any case, when CPD is suspected, the use of oxytocin is strongly contraindicated.

ABDOMINAL PALPATION

Abdominal palpation begins with an assessment of uterine activity and the character and strength of contractions. Leopold's manoeuvres will suggest the possibility of fetal macrosomia, abnormality of fetal presentation, position, head flexion or poor engagement of the presenting part. It is mandatory to determine the degree of engagement of the fetal head – if more than one fifth of the fetal head is palpable abdominally, then it would be prudent to reconsider the wisdom of a vacuum delivery – or perhaps perform the pro-

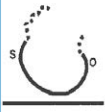
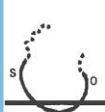
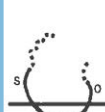



| NOT ENGAGED | NOT ENGAGED | NOT ENGAGED | NOT ENGAGED | JUST ENGAGED | DEEPLY ENGAGED |
|---|---|---|---|---|---|
| MID | | | MID | | |
| sinciput: (s) +++++ occiput: (o) +++ 5/5 | sinciput: (s) +++++ occiput: (o) +++ 4/5 | sinciput: (s) +++ occiput: (o) ++ 3/5 | sinciput: (s) ++ occiput: (o) + 2/5 | sinciput: (s) + occiput not felt 1/5 | head not palpable above brim 0/5 |
|  |  |  |  |  |  |

Fig 11. Determine the degree of engagement of fetal head.

cedure in theatre as a trial of vacuum (Fig 11). Caesarean section is preferred to a vacuum delivery in the unengaged head. If abdominal examination suggests a normal-sized infant with an engaged head, one may proceed to a vaginal examination.

PELVIC ASSESSMENT

Armed with the knowledge of normal pelvic dimensions and architecture, the obstetrician or midwife performs a meticulous clinical pelvimetric evaluation to identify cases of pelvic contraction. If absolute CPD is a reality, clearly the vaginal birth is abandoned and a caesarean section performed. However, if the pelvis may allow a vaginal delivery, particularly if the fetal head is asynclitic, malpositioned or poorly flexed, then the possibility of a vacuum delivery may be entertained.

EVALUATION OF THE PRESENTING PART

The foundation of a successful vacuum delivery is meticulous clinical selection of suitable cases. If the cervix is not fully dilated, delivery by vacuum is out of the question. Excessive moulding, particularly if irreducible, may point to CPD. Likewise a great deal of caput makes assessment difficult and calls the procedure into question. Certainly the Silc Cup instrument is unsuitable for cases with a lot of moulding, and metal cup application will be more appropriate.

Confirm that the presenting part is in fact properly engaged, and that the clinician is not merely feeling moulding and caput below the ischial spines. Carefully establish the occi-

Confirm that the presenting part is in fact properly engaged, and that the clinician is not merely feeling moulding and caput below the ischial spines. Carefully establish the occi-

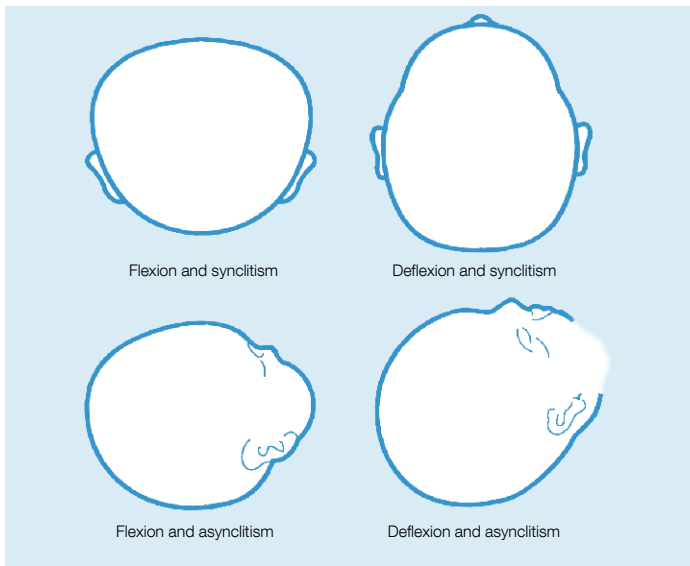


Fig 12. Evaluation of the presenting part.

pital position, and whether the anterior fontanelle is easily palpable – this would suggest deflexion of the fetal head. Determine the position of the posterior fontanelle, and whether any significant asynclitism exists (Fig 12).

The membranes must be ruptured if a vacuum delivery is contemplated and the colour of the liquor examined to establish the presence of any meconium. The clinician's aim is to make a reliable and accurate evaluation of the fetopelvic relationship, and exclude CPD as a cause of arrest of the progress of labour. If relative CPD is suspected, instrumental delivery should proceed with circumspection in theatre, or be abandoned altogether.

SUMMARY:

ASSESSMENT AND SELECTION OF CASES

- Clinical evaluation – review maternal condition, progress of labour and assess results of clinical examinations.
- Abdominal palpation – check on uterine contractions, degree of engagement of the presenting part, and Leopold's manoeuvres. Estimate fetal size and fetal heart rate.
- Pelvic assessment: establish if relative or absolute CPD is present.
- Evaluate presenting part: especially position, engagement, asynclitism, and if caput or moulding are present.
- If conditions warrant, a trial of vacuum in theatre with recourse to caesarean section is prudent.

8. BEFORE PROCEEDING TO VACUUM ASSISTED DELIVERY

COUNSELLING

Maternal co-operation and consent is vital prior to any instrumental delivery, and it certainly may be wise to share one's intentions with the family concerned. Careful explanation and counselling will do much to foster co-operation of the patient. If appropriate, written consent may be necessary prior to any obstetric intervention.

GENERAL MEASURES

Hydration and pain relief

Obviously, anybody in labour must be kept well-hydrated with an empty bladder, and afforded adequate analgesia. Outlet vacuum extractions require no specific analgesia unless an episiotomy is contemplated. Perineal infiltration should suffice, or if procedures in the mid-pelvis with rotation are indicated, then a pudendal block may prove useful.

Accompanying person

Every woman in labour deserves the encouragement and companionship of a person she trusts. The midwife conducting the delivery will palpate the uterine contractions and encourage bearing down particularly in cases of an epidural where sensation is lost. Injury to the foetus is more likely to result if the operator substitutes traction for maternal expulsive effort.

Maternal position

For outlet vacuum delivery, maternal position is not critical. However, whenever more demanding interventions appear necessary, then a dorsal lithotomy position is appropriate. This would allow the correct direction of downward traction along the line of the birth canal axis and facilitate episiotomy repair should this be required.

Preparation of the vulva

The woman is prepared according to the institutional custom, and cleaned and draped appropriately. Routine bladder catheterisation is not required, since good midwifery mandates the maintenance of an empty bladder at all times during labour.

Testing the system

Prior to performing the procedure, the equipment must be examined for defects or excessive wear. Test all components especially the vacuum pumps, tubings and canister. All valves or perishable parts must be replaced regularly to avoid finding unserviceable equipment just when its use appears to be vital. Always keep a sterilized set available, especially on a busy labour ward.

ONE FINAL CHECK:

Always review the list of indications and contra-indications before applying a vacuum cup. Be ever vigilant for the presence of CPD.

SUMMARY:
BEFORE PROCEEDING

- Counsel the patient and her family, and obtain consent for the procedure.
- Pudendal block is useful especially for abnormal positions, otherwise perineal infiltration with a local anaesthetic will suffice.
- Routine lithotomy is not necessary for outlet procedures.
- Episiotomy is only required if obstetrically indicated.
- Test the system before use, and keep a serviceable set sterile and available.
- Review the list of indications and contra-indications before applying the vacuum cup.

9. PRINCIPLES, TECHNIQUES AND CLINICAL USE OF THE VACUUM EXTRACTOR

CHOICE OF CUPS

Abdominal and vaginal examination will indicate the type of instrument to be used. Always use as big a cup as practical. The Bird cups are more manoeuvrable than the Malmström and soft cups. With the Bird modifications the «anterior cup» is used for occipito-anterior positions, and the «posterior cup» for occipitolateral and occipito-posterior positions. The Bird «posterior cup» is not recommended if the occipito is anterior – in this situation use the Malmström device or if the head is below spines or on the perineum, the Silc Cup is advised.

The 60 mm diameter cup is less manoeuvrable than the 50 mm device. Always use as large a diameter as possible to reduce the risk of soft tissue injury. The 40 mm cup is only used for delivering the second twin. When correctly placed the vacuum cup is positioned centrally over the point of cranial flexion, the pivot point. The edge of a 60 mm cup will be 30 mm behind the anterior fontanelle in the midline over the sagittal suture (Fig 13).

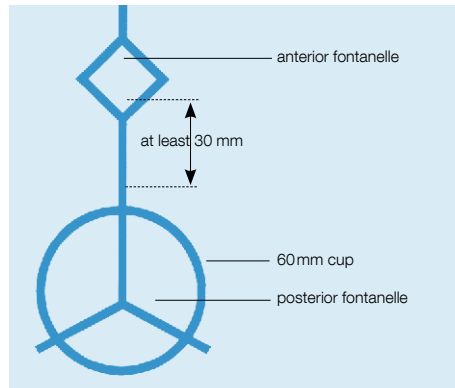


Fig 13. The pivot point (flexion point)

TECHNIQUE USING THE METAL CUP

Assemble the device and connect it to the vacuum canister. Check that the equipment is functional, and ascertain that no contra-indications to vacuum delivery exist. Repeat the vaginal examination to establish the exact position of the occiput and posterior fontanelle, and the degree of caput and moulding (Fig 14).

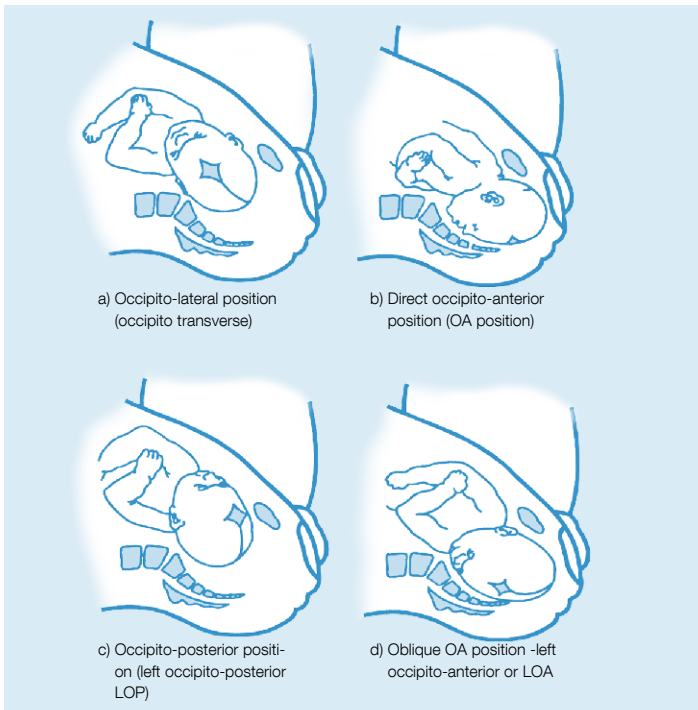


Fig 14. Establish the exact position of the occiput and posterior fontanelle.

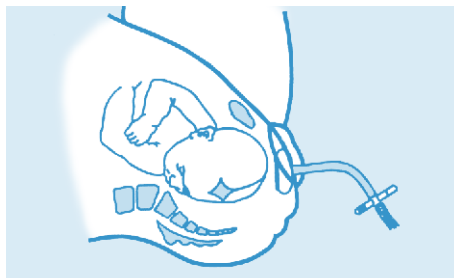


Fig 15. Occipito-anterior position Malmström cup applied over flexion point.

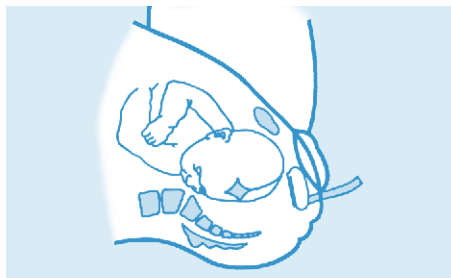

Fig 16. Bird anterior cup suitable for occipito-anterior positions. The suction tube is towards the sinciput.

Lubricate the cup with antiseptic obstetric cream, part the labia with the left index finger and thumb, and gently introduce the metal cup into the vagina. It should sit comfortably between the head and the maternal perineum. The cup is positioned centrally over the posterior fontanelle; taking into consideration that asynclitism could be present.

Ensure a 30 mm distance between the cup margin and the anterior fontanelle. If the cup is applied less than 30 mm from the anterior fontanelle, then extension of the fetal head during traction may result (Fig 15). When the Bird cup is used, the suction tube must be towards the sinciput. Ensure that no vaginal skin is pinched between the cup and the fetal scalp (Fig 16).

A vacuum pressure of -20 kPa is formed by the assistant, and then the operator's index finger is run around the perimeter of the cup's rim to once again ensure no maternal tissue is trapped under the cup. Once again check that the application is correctly positioned centrally over the posterior fontanelle, with a 30 mm gap between the cup and the anterior fontanelle (Fig 17).

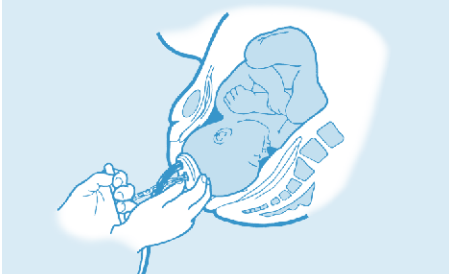


Fig 17. Check application is correct over posterior-fontanelle and flexion point (Bird anterior cup, ROA position).



Fig 18. Direction of traction is in the axis of the birth canal, perpendicular to the cup.

Increase the vacuum to -80 kPa and wait for 2 minutes to allow a chignon to form. It is not necessary to allow this increase in step-wise form. Traction before the formation of a chignon may result in cup displacement.

TRACTION

If the operator is right handed, assume a sitting position and grasp the traction handle with the right hand, with the left index finger resting on the scalp and rim of the cup and the left thumb on the cup. This allows appreciation of descent of the presenting part and not just the caput, and detects separation of the cup from the scalp. Cup application is rechecked and at the next uterine contraction the traction is applied smoothly and gently in the axis of the birth canal. This may be downwards at first, later moving horizontally and then upwards as the head crowns (Fig 18). The direction of traction is perpendicular to the cup. Traction is reduced if the cup begins to detach and an audible hiss is heard. For mid-pelvic rotational deliveries oblique traction may be required to maintain the axis of the fetal head in line with the

pelvic axis. The fingerthumb position of the left hand is maintained during traction until the head crowns, especially if traction is oblique. Traction is continued for the duration of a uterine contraction, and then relaxed. Avoid rocking or jerking the cup, since scalp laceration may result. The assistant encourages the mother to bear down during contractions, and monitors the fetal heart thereafter.

The first pull flexes the head and should result in descent. There should be marked progress during subsequent contractions and after three pulls delivery of the head should be imminent. Routine episiotomy is not required, and only performed if indicated. After delivery of the head the vacuum is released, the cup is removed and delivery completed in the usual fashion.

NOTES ON USING THE BIRD POSTERIOR CUP

The Bird posterior cup is used for occipito-lateral (Fig 19) and occipito-posterior positions (Fig 20).

While use of the «Bird Posterior Cup» follows the steps outlined above, some points need to be mentioned.

When the baby is in the occipito posterior or similar posi-

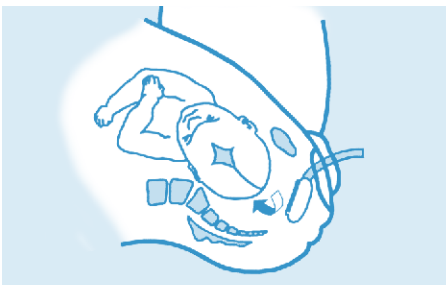


Fig 19. Occipito-lateral position (occipito-transverse). Bird posterior cup required.

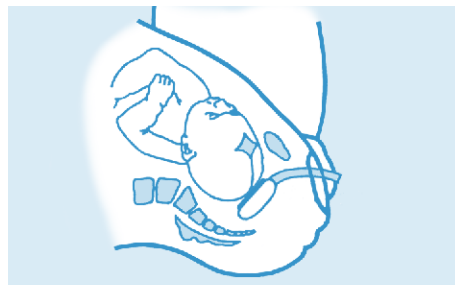


Fig 20. Occipito-posterior position (LOP). Bird posterior cup required.

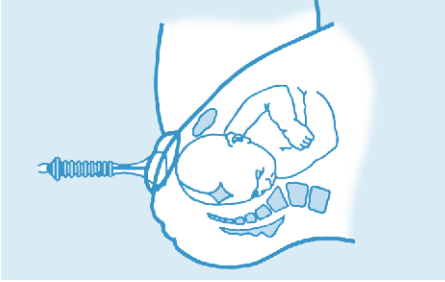


Fig 21. Presenting part well below spines, well flexed right occipito-anterior. The Silc Cup may expedite delivery.

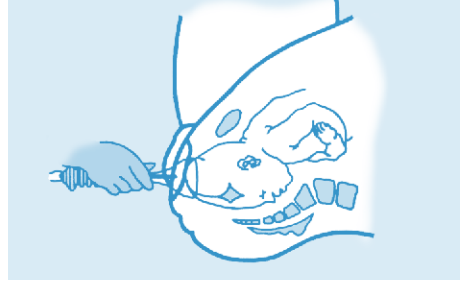

Fig 22. Fetal head on perineum, Silc Cup expedites delivery.

tions, they invariably have a significant caput on the parietal aspect of head, which may impede correct posterior placement of the cup. By lifting the caput the cup may be correctly positioned in the sacral hollow, over the posterior fontanelle.

When the cup is correctly positioned in these posterior cases it will not be visible at the introitus. Perpendicular traction may not be possible when the cup is correctly applied to a malpositioned head in the midpelvis. Since oblique traction may cause cup detachment, the left thumb or index finger may usefully apply counterpressure to the cup rim likely to lift off the fetal head.

When correctly positioned, downward traction allows spontaneous rotation with descent, but it is dangerous to attempt manual rotation by rotating the cup. If anterior rotation does not occur and the head is delivered in the face-to-pubes position, it may be necessary to cut an episiotomy. Some authorities suggest that in the occipito-posterior position an

episiotomy permits better application of the cup, since the maternal tissues will not obstruct the vacuum tube or the traction device.

The technique employed for using a disposable Bird Cup is identical to that described above.

TECHNIQUE USING THE SILC CUP

Soft cups are particularly useful when the exhausted mother has endured the tedium of a long labour, and requires assistance during the second stage. When the fetal head is on the perineum, well flexed and occipitoanterior, the Silc Cup device may expedite delivery (Fig 21 and 22). The device is unsuitable for midcavity deliveries with abnormal positions, particularly in the presence of caput and moulding.

For the Silc Cup delivery of a baby well below spines with its head flexed in the occipito-anterior position, lithotomy position is not mandatory, given that downward traction required for midcavity deliveries may not be needed. Delivery may be undertaken in the dorsal, left lateral or even squatting positions.

APPLICATION OF THE SILC CUP

After an application of anti-septic obstetrical cream, the cup is squeezed at its widest point to facilitate gentle introduction through the vulva (Fig 23). The cup must sit easily and comfortably

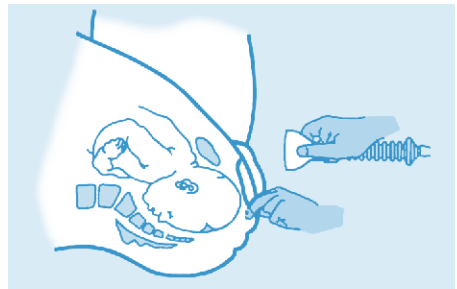


Fig 23. Silc Cup is lubricated and compressed, then gently introduced through the vulva.

between the fetal head and perineum, then moved to ensure its correct position over the posterior fontanelle with 30 mm between the cup margin and the bregma. The index finger is passed around the rim to ensure no maternal tissue is pinched between the fetal scalp and the cup, and a vacuum of -20 kPa induced. The cup tends to flatten against the fetal scalp. Position and application are rechecked. A full vacuum of -80 kPa is obtained, and traction commenced at the next uterine contraction (Fig 24). Since a chignon does not form in soft cups, there is no 2 minute waiting period as in metal cups.

TRACTION

Traction is synchronous with uterine contractions, the right hand supplying firm, gentle tension, and the finger of the left hand on the scalp/rim margin to ensure the head itself descends, and not merely the scalp. Three gentle pulls should be sufficient to deliver most babies, especially if the cup is correctly applied and the traction is in the direction of the maternal pelvic axis (Fig 24).



Fig 24. Gentle traction in the direction of the maternal pelvic axis.

An audible hiss suggests traction is too severe and should be relaxed to prevent cup separation. This scenario is less common with electric devices than non-electric. If this occurs the cup may be reapplied not more than twice, otherwise the procedure must be abandoned. Generally, rou-

tine episiotomies are superfluous and only cut if obstetrically indicated, for example fetal distress. After delivery of the head, the cup is released and the rest of the infant delivered in the normal way. Traction is not applied between contractions, but it may sometimes be helpful to hold the head in place between contractions so it does not move back up the birth canal.

SUMMARY:

CLINICAL USE OF THE VACUUM EXTRACTOR

- Use the biggest cup practical.
- For the well-flexed occipito-anterior head, below the spines or on the perineum, a Silc Cup is useful.
- The Silc Cup is unsuitable for midcavity deliveries with abnormal positions, especially with caput or moulding.
- If the occiput is anterior, at spines, with some degree of caput and moulding, a Malmström cup is suitable, or the Bird anterior cup.
- For occipito-posterior or occipito-lateral positions, the Bird posterior cup is suitable.
- The cup must be positioned over the posterior fontanelle, at the «pivot point», with a 30 mm gap from the rim to the anterior fontanelle.
- The metal cups require a vacuum of -80 kPa, and a chignon which takes 2 min to form.
- The Silc Cup does not require a chignon.
- Traction is applied along the pelvic axis with contractions. Descent must occur with traction.

10. VACUUM ASSISTED DELIVERY (VAD) AT CAESAREAN SECTION

VAD at the time of caesarean section has been practiced for several decades, and a description of soft cup VAD at caesarean section was published in 1982 in the American Journal of Obstetrics and Gynaecology by Marco Pelosi.

However a purpose – designed device, the **CaesAid Cup** (Fig. 25), has recently become available, suitable for VAD at caesarean section.

DESCRIPTION OF THE CAESAID DEVICE

The device is made of silicone, with a 60 mm diameter cup surmounted by a flange of 45 mm. The length is 100 mm, with a metal tube allowing attachment to silicone tubing. It is soft and pliable, allowing ease of use, with no damage to the unborn child.



Fig 25. *CaesAid device.*

DESCRIPTION OF USE OF CAESAID CUP

The cup is employed at either elective planned caesarean section, or if desired and appropriate, at an emergency caesarean section. Carefully check the equipment prior to use. The uterus is exposed in the usual manner, and the lower section muscle opened conventionally. The fetal presenting part is palpated and visualized and excess liquor suctioned to allow direct exposure. The CaesAid device is placed, without lubrication, directly over the posterior fontanelle. A finger is run around the rim of the device to ensure no tissue or cord is trapped between the cup and the fetal scalp. Ensure that the exact desired position of the cup over the posterior fontanelle is confirmed.

Establish a vacuum of 60kPa using an electric pump – this need not to be done stepwise or incrementally. Gently draw the presenting part downwards through the uterine incision, then release the vacuum and remove the cup, to allow delivery of the baby in the usual fashion.

POSSIBLE ADVANTAGES OF CAESAID DELIVERY AT CAESAREAN SECTION

Until the advent of this device, delivery of the fetal head at caesarean section has been by means of the forceps (i.e. Wrigley's forceps) or manually by grasping the head and applying traction. However possible advantages of CaesAid delivery include a smaller skin incision which is easier and quicker to repair, and a smaller incision in the lower segment of the uterus. There may also be less blood loss due to the smaller incision.

SUMMARY:
USE OF THE CAESAID AT CAESAREAN SECTION

- The device may be used for both elective and emergency caesarean section
- It possibly allows a smaller incision with less blood loss, and consequently quicker repair
- The uterus is opened in the conventional manner, and the fetal presenting part displayed
- The cup is applied to the posterior fontanelle after excess liquor has been suctioned
- The finger explores the rim of the cup to ensure no tissue or cord is trapped between the cup and the fetal scalp
- The vacuum is immediately increased to 60kPa by means of an electric pump. The head is drawn down through the uterine incision, the cup released, and the baby delivered in the usual way.

11. COMPLICATIONS OF VACUUM ASSISTED DELIVERY

The importance of meticulous clinical evaluation, careful vaginal examination, thorough preparation and gentle execution of the vacuum delivery cannot be over-emphasized. Rigorous judgement is the watchword – if circumstances are difficult, a trial of vacuum in theatre will allow recourse to immediate caesarean section without the need to succeed with a vaginal delivery at all costs. There is no place for heroic instrumental deliveries – good maternal and fetal outcomes are paramount. A trial of vacuum may end in a caesarean section, without the pejorative descriptive term «failed vacuum» and its negative implications. A Caesarean section is often preferable to a difficult and heroic instrumental delivery.

CAUSES OF FAILURE

No descent on traction

Incorrect cup placement (for example, near the anterior fontanelle) or poorly directed traction efforts are the cause of most failed operations (Fig 26). If no descent of the head (not the chignon) is detected during traction, carefully review the

orientation of traction efforts. If the vector or direction of traction is incorrect, not only will the presenting part fail to descend, but the cup may detach or fetal injury may occur. If, after thoughtful consideration the traction is repeated and is in the correct direction with the cup correctly

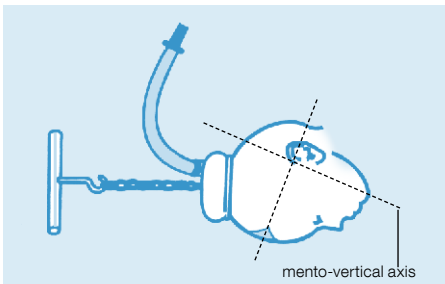


Fig 26. Failure of procedure: cup too close to anterior fontanelle, not over flexion point (refer Fig 4).

placed centrally over the flexion point but with no descent, then cephalopelvic disproportion may be present, and a caesarean section is advisable.

Bird coined the term «negative traction», when traction draws the fetal scalp down but there is failure of descent of the skull. This may result in intracranial or scalp injury, haemorrhage or haematoma (Fig 27).

Detachment of the cup

The cup may detach for the abovementioned reasons, or if a large caput succedaneum does not allow a satisfactory chignon to form. The Silc Cup device does not rely on the formation of a caput, and so any meaningful caput may result in the cup slipping off. Generally the cup may be reattached twice after detachment. It is important not to resort to a forceps delivery if the cup slips off repeatedly and the wise clinician would rather opt for a caesarean section.

Cup detachment is more common with the soft cups, because no chignon is formed, but soft cups are associated with less fetal trauma than metal cups. Injury to the scalp is associated with sudden detachment, especially if this occurs after the cup has been subject to strong traction (Fig 27). If maternal tissue has been pinched between the fetal scalp and the cup, it may detach.

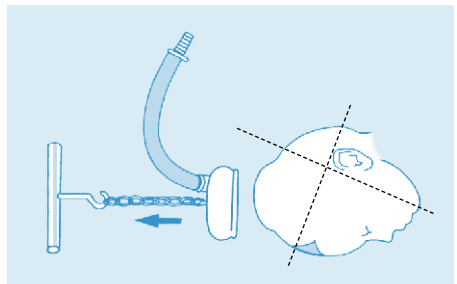


Fig 27. Cup badly positioned. Sudden detachment may cause scalp injury.

Occasionally detachment occurs when the traction is too oblique, too strong, or pulling without a uterine contraction. Application of the cup obliquely over the parietal area away from the sagittal suture will result in poor vacuum formation and cup slippage.

A faulty apparatus may not allow adequate vacuum formation and the cup will not adhere under these circumstances.

Duration of the procedure

Duration of the procedure is defined as the interval from initial vacuum formation until delivery of the head. Since it takes 2 minutes at most to form a chignon, deliveries ought to be completed within 15 minutes. If a vacuum of -80 kPa or less is maintained for less than this period it is unlikely that the chignon will harm the baby or result in damage to the fetal scalp. Fifteen minutes will suffice to determine if the vacuum procedure has failed, and a caesarean section is required.

Since around three pulls during uterine contractions will deliver most babies, it is clear that it is never necessary to persist for longer than 15 minutes.

How much traction is required?

It is difficult to determine the upper limit of strength and duration of traction required but each downward traction must result in progress towards delivery. If a steady pull during a contraction with maternal bearing down and with a correctly applied cup along the preferred axis does not result in descent, the procedure must be reviewed and alternative arrangements for delivery made. The aim of the clinician is to use the least amount of traction causing descent,

with the least number of pulls. Clinical judgement is more important than dogmatic adherence to prescriptive rules.

Maternal effects and complications

Randomised trials suggest that vacuum deliveries cause significantly less maternal morbidity than do forceps deliveries. Maternal injuries associated with vacuum delivery are rare, but include perineal lacerations and injury to the vulva, vagina and cervix. There is significantly less anal sphincter trauma in vacuum deliveries than occurs with forceps deliveries, suggesting that vacuum delivery is considerably safer for the mother than forceps delivery.

FETAL EFFECTS

Minor scalp trauma

The chignon induced in the metal vacuum cup usually diminishes rapidly, and like a caput succedaneum disappears over a few hours, being insignificant after a day or two. However, difficult extractions, particularly if the cup detaches, or with prolonged traction, may cause lacerations or injury to the scalp. Abrasions or bruising caused around the perime-

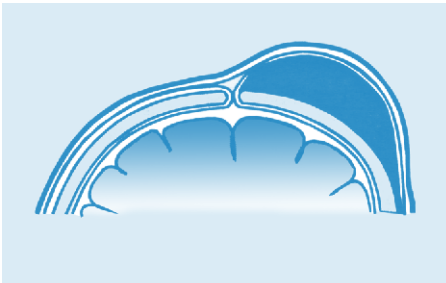

Fig 28. *Cephalhaematoma*

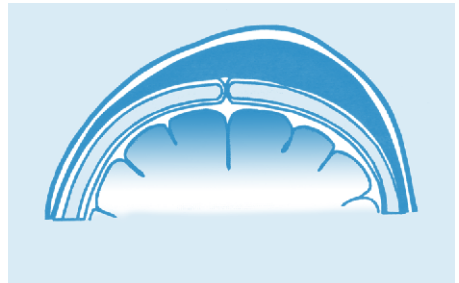


Fig 29. *Subaponeurotic (Subgaleal) haematoma*

ter of the cup usually heal rapidly and may be treated with a topical antibiotic until healing is satisfactory. Suturing is rarely required for scalp lacerations. Soft vacuum cups are less likely to cause fetal scalp injury despite having a higher rate of failure than metal cups.

Cephalhaematomas and subaponeurotic haemorrhage

Cephalhaematomas are limited collections of blood that accumulate under the fetal periosteum, following vacuum delivery (Fig 28). While subcutaneous bleeding forms a fluctuant swelling that resolves rapidly and spontaneously, cephalhaematomas take considerably longer, and may take several weeks to be resorbed. Expectant conservative management is appropriate, but babies with larger cephalhaematomas are best referred for a paediatric opinion and further management.

A subaponeurotic (subgaleal) haemorrhage occurs when bleeding occurs in the space beneath the aponeurosis of the scalp (Fig 30). Since the subaponeurotic space is a large potential cavity over the entire area of the cranial vault, a considerable volume of venous bleeding may occupy this potential space, with a large volume of blood accumulating. The condition is more common following a difficult delivery, especially if fetal hypoxia or a coagulopathy are present. Negative traction, where traction does not result in descent of the presenting part but rather of the scalp, may cause a subaponeurotic haemorrhage.

Obviously all babies must be examined immediately after delivery and again some interval later to detect any scalp trauma, haematomas, swelling or haemorrhage. A fluctuant,

diffuse swelling alerts the clinician or midwife to the condition, and the baby is observed for pallor or circulatory collapse since a large, fluctuant haematoma may contain a significant percentage of the fetal blood volume. Expert paediatric assistance is important and the baby may require transfusion with blood plasma or a colloid.

While these complications don't often occur after Silc Cup delivery, difficult metal cup extractions, with prolonged traction, especially if the cup detaches, predispose to this complication.

Intra-cranial haemorrhage

Subdural bleeding from injury to intracranial veins may follow difficult vacuum extractions. Damage to the falx cerebri or tentorium cerebelli with trauma to the delicate venous sinuses may occur by attempting a vacuum delivery in a poorly selected case with CPD. Intracranial haemorrhage may be revealed in the newborn by modern imaging techniques, following abnormal neurological signs in the baby having had a vacuum delivery. The baby may exhibit irritability, neonatal depression, apnoea or convulsions. Management is by an expert paediatric team. Perinatal deaths following use of the vacuum extractor are rare, and not generally attributable to the device.

Cup detachment should not be regarded as a safety mechanism of the vacuum, but should be seen as a warning sign of CPD or of incorrect application of the cup. If detachment occurs, the cup may be re-applied only if the clinician is convinced that the cause of the detachment is not CPD. Clearly

the best way to avoid any complication of a vacuum delivery is by careful assessment before attempting the procedure, and adherence to the guidelines for vacuum delivery. Fetal and maternal trauma following Silc Cup delivery is by the very nature of the device most unlikely if the clinician adheres to recommended guidelines.

Not all scalp trauma or intracranial haemorrhage is caused by the vacuum cup – for example cephalhaematomas and other scalp trauma may be found after vaginal delivery, or even following caesarean section. The paediatrician must always be informed of the mode of delivery of the infant. Other forms of fetal complications following vacuum delivery, for example retinal haemorrhage, are rare and resolve spontaneously without any specific intervention being required. Data on the long term outcome of children delivered by vacuum delivery are reassuring when compared either with children delivered spontaneously or by obstetric forceps.

It is important that a careful record of the instrumental delivery be included in the patient's notes. A suitable proforma has been designed by the Royal College of Obstetricians and Gynaecologists. This is a useful summary of the instrumental delivery with comprehensive details recorded (Fig. 30).

APPENDIX 1

OPERATIVE VAGINAL DELIVERY RECORD

Date.....

Operator Name Grade

Supervisor Name Grade

Patient Details

Indication(s) for delivery:

Classification of OVD: outlet / low / midcavity Rotation > 45°: yes / no

Fetal wellbeing: CTG: normal / suspicious / pathological Liquor: clear / meconium

| | |
|---|--|
| <p>Prerequisites:</p> <p>Place of delivery: room / theatre</p> <p>Analgesia: local / pudendal / regional</p> <p>Consent: verbal / written</p> <p>Catheterised: yes / no</p> | <p>Examination</p> <p>1/5th per abdomen:</p> <p>Dilatation:.....</p> <p>Position:</p> <p>Station:</p> <p>Moulding:.....</p> <p>Caput:.....</p> |
|---|--|

| | |
|--|--|
| <p>Procedure</p> <p>Instrument used:</p> <p>Vacuum extractor : silastic / Kiwi / metal anterior / metal posterior</p> <p>Forceps: rotational / non-rotational / outlet</p> <p>Number of pulls:</p> <p>Traction: easy / moderate / strong</p> <p>Maternal effort: minimal / moderate / good</p> <p>Placenta: CCT/ manual</p> <p>Episiotomy: yes / no</p> <p>Perineal tear: 1st degree <input type="checkbox"/></p> <p> 2nd degree <input type="checkbox"/></p> <p> 3rd / 4th degree <input type="checkbox"/> (complete pro forma)</p> <p> Other <input type="checkbox"/> (complete suturing pro forma if necessary)</p> <p>EBL:</p> | <p>Multiple instrument use: yes / no</p> <p>Examination before second instrument</p> <p>1/5th per abdomen:.....</p> <p>Position:</p> <p>Station:</p> <p>Moulding:.....</p> <p>Caput:.....</p> <p>Reasons for second instrument:</p> <p>.....</p> <p>.....</p> <p>.....</p> |
|--|--|

Baby: M / F Birth weight: (kg) Apgar: 1..... 5..... 10..... Cord pH: Arterial..... Venous.....

Post-delivery care:

Level of care: routine / high dependency

Syntocinon infusion: yes / no

Catheter: yes / no Remove

Vaginal pack: yes / no Remove

Diclofenac 100 mg PR: yes / no Analgesia prescribed: yes / no

Thromboembolic risk: low / medium / high

Thromboprophylaxis prescribed: yes / no

Signature: Date:

RCOG Green-top Guideline No. 26 17 of 19 © Royal College of Obstetricians and Gynaecologists

Fig. 30. RCOG operative vaginal delivery record

SUMMARY:
COMPLICATIONS OF VACUUM ASSISTED DELIVERY

- Rigorous clinical judgement is the basis of a safe and effective vacuum delivery procedure.
- Causes of failure are commonly due to incorrect angle of traction, incorrect cup placement, or cephalopelvic disproportion.
- Cup detachment may occur for the above reasons, or in the presence of excessive caput or equipment failure.
- Ensure the procedure takes no longer than 15 minutes, with a maximum vacuum of -80 kPa.
- Maternal damage is rare, and is mostly lacerations to the vagina, cervix or vulva.
- Fetal scalp trauma, some bruising or lacerations are generally not significant causes of fetal morbidity.
- Cephalhaematomas or subaponeurotic haemorrhage may represent significant injury, and babies so diagnosed ought to be referred for a paediatric assessment and possibly further management.
- A written summary of all instrumental deliveries, for inclusion in the maternal records.

12. TRAINING MEASURES

Many midwives and obstetricians acquire proficiency through experience and self instruction, but skill in the use of a vacuum extractor is best acquired under the supervision of a trained operator. Use of the device should form a part of all obstetric and midwifery training programmes.

It is true that caesarean section has become a relatively safe operation which is easy to perform by anyone with basic surgical skills. However, it is not without morbidity and a well-selected case suitable for a vacuum delivery is still safer for the mother than a surgical procedure requiring some form of anaesthesia. Any training programme must begin with a review of maternal pelvic and fetal anatomy, with an appreciation of the process of normal labour.

Thereafter some instruction in the types of vacuum delivery instruments is useful, with teaching of the indications and contra-indications for vacuum delivery. The student must handle the various devices, and learn how to assemble the instruments and use them. At this point it would be useful to demonstrate the techniques of vacuum delivery using an obstetric doll and the obstetric pelvis. When this has been mastered, the beginner should watch the techniques using instructional visual training products followed by assisting in the labour ward during actual deliveries.

After several procedures have been witnessed, they may be tried under the personal supervision of an experienced clinician. Only then should the trainee attempt the procedure unaided.

The Silc Cup device forms an excellent introduction to learning the clinical skills involved, particularly in delivering babies well below the spines in the occipito-anterior position. The vacuum delivery process does not end when the vacuum is released, and the student must learn to counsel the mother and follow-up the baby to ensure that no complications arise.

It is important to examine the baby regularly after delivery with particular emphasis placed on assessment of the fetal scalp, to effect timely detection of the occurrence of haematomas or other conditions.

**SUMMARY:
TRAINING MEASURES**

- The trainee must understand the theoretical basis of obstetrics and vaginal birth.
- The theory of vacuum delivery is grasped, then the method is demonstrated on an obstetrical doll and pelvis.
- Visual instruction products should be viewed, and the exact procedure is revised.
- The trainee observes several vacuum deliveries before attempting them under supervision, initially with a Silc Cup.
- An experienced clinician is initially available until the technique has been mastered.
- The trainee must be taught to assess the fetal condition soon after vacuum delivery to detect scalp trauma.

13. CLEANING AND STERILIZING THE EQUIPMENT

CLEANING + STERILIZING

Bird anterior or posterior vacuum extractor cups with traction chain

1. Remove the handle.
2. Slide the white retaining ring off the tube connector and separate the tubing from the cup.
3. Flush the tubing with a strong stream of COLD water.
4. Remove the nylon bottom plate mesh.
5. Wash the traction handle, nylon bottom plate mesh*, cup and tube.
6. Reassemble the cup using either the clean mesh (or a replacement as preferred) and attach the tube and retain with the white locking ring.
7. Pack the assembled cup and tubing with the traction handle.
8. Autoclaving should be carried out at 134°C (273.2°F) minimum to 137°C (278.6°F) maximum for 3 minutes.

* Some hospitals prefer to discard the bottom plate mesh rather than sterilize it.

Malmström Cups

1. Remove the long silicone suction tube leading from the handle to the vacuum reservoir.
2. Disassemble the cup by:
 - 2.1 Release the chain from the traction handle by pulling the chain while holding the handle with the stop clip downwards.
 - 2.2 Tap the mouth of the suction cup on a hard surface to dislodge the flat metal plate inside. Draw this plate and the attached chain completely out of the suction cup.
 - 2.3 Remove the traction handle from the attached silicone suction tube.
 - 2.4 Remove the silicone suction tube from the suction cup.
3. Flush the tubing with a strong stream of COLD water.
4. Wash all the metal parts and the tubes.
5. Reassemble prior to sterilisation as:
 - 5.1 Push one end of the short silicone tube completely onto the tube connector of the suction cup.

- 5.2 While holding the cup with the wide opening up, let the chain drop through the hole in the cup and down through the tubing so that the bottom plate fits into place.
- 5.3 Let the protruding end of the chain drop through the traction handle and push the tube all the way onto the adjacent tube-connector-piece of the traction handle.
- 5.4 Holding the handle in a horizontal position with the clip upwards grasp the chain and pull it tight and push the clip into the link.
6. Refit the long vacuum tube.
7. Pack the assembled cup and tubing.
8. Autoclaving should be carried out at 134°C (273.2°F) minimum to 137°C (278.6°F) maximum for 3 minutes.

Silc Cup

1. Remove the silicone suction tube.
2. Flush the tubing with a strong stream of COLD water.
3. Flush the inside canal of the cup with a strong stream of COLD water.
4. Wash the cup and tube.
5. Refit the tubing onto the cup.
6. Pack the assembled cup and tubing.
7. Autoclaving should be carried out at 134°C (273.2°F) minimum to 137°C (278.6°F) maximum for 3 minutes.

14. SUMMARY AND CONCLUSIONS

The technique of vacuum assisted delivery was introduced into modern obstetric practice by Tage Malmström, the Swedish obstetrician, in the 1950's. The device has become the preferred method for operative vaginal delivery world wide, and in the United States twice as many vacuum deliveries as forceps deliveries are performed.

The procedure should not be attempted at a gestational age of less than 36 weeks. Application of forceps after an attempted vacuum delivery is generally not advisable. If a difficult vacuum procedure is anticipated, it may be done in an operating theatre with recourse to a caesarean section should the trial of vacuum be unsuccessful.

The correct application of a vacuum cup is directly overlying the «flexion point», a point on the sagittal suture 20 or 30 mm in front of the posterior fontanelle. The procedure is abandoned if the cup detaches more than twice, if there is no descent of the presenting part on steady traction, or if the cup application time exceeds 15 minutes. Fetal distress is not a contra-indication to the procedure.

The Silc Cup device is suitable for well-flexed occipito-anterior cases with the presenting part below spines. The rigid metal cups are indicated for extractions from occipito-posterior, occipito-transverse, deflexed, and asynclitic positions. Soft vacuum cups are less likely to cause fetal scalp injury but have a higher rate of failure than rigid cups. Cup detachment should not be regarded as a safety mechanism of the vacuum but should be seen as a warning sign of CPD

or of incorrect application of the cup. If detachment occurs, the cup should be reapplied only if the operator is convinced that the cause of detachment is not CPD.

Incorrect application and traction in the wrong direction are common causes of cup detachment. An episiotomy is probably unnecessary in the majority of extractions. Subaponeurotic (subgaleal) haematoma are rare but potentially dangerous complications of vacuum delivery: early recognition and treatment are critical.

The CaesAid device has been especially designed to facilitate easy delivery of the fetal head at Caesarean section, and may offer advantages over forceps and manual extraction techniques.

Data on the long-term outcome of children delivered by vacuum delivery are reassuring, since the vacuum delivery system is safe and efficient in the properly selected case.

The obstetrician or midwife must be carefully trained before use of the vacuum extractor, and supervised by a competent authority before attempting vacuum deliveries unsupervised.

EQUIVALENT NEGATIVE GAUGE PRESSURES

| kPa | Kg/cm ² | mmHg | bar |
|-------|--------------------|-------|--------|
| - 13 | - 0.13 | - 100 | - 0.13 |
| - 27 | - 0.27 | - 200 | - 0.26 |
| - 40 | - 0.41 | - 300 | - 0.39 |
| - 53 | - 0.54 | - 400 | - 0.53 |
| - 67 | - 0.68 | - 500 | - 0.66 |
| - 80 | - 0.82 | - 600 | - 0.79 |
| - 93 | - 0.95 | - 700 | - 0.92 |
| - 101 | - 1.03 | - 760 | - 1.0 |

DISCLAIMER

The opinions expressed in this text reflect the thoughts and experience of the author alone. Whilst the information and advice in this book is believed to be true and accurate at the date of publication, neither the author, publisher or any manufacturer can accept legal liability for any errors or omissions that may occur.

Imprint

This brochure was produced in collaboration with

Dr Peter de Jong MD

MBChB, FRCOG, FCOG, MMed

Published by: Medela AG

Copies and reprints only by permission of Medela AG. 2015

© Medela AG, 6340 Baar, Switzerland

Vacuum Assisted Delivery Procedures